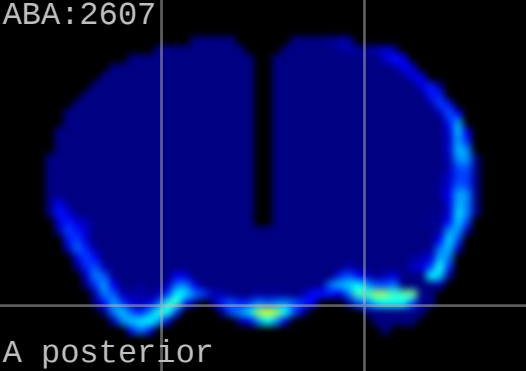


ABA:2607

A posterior

An axial brain scan image showing a cross-section of the brain. The image is predominantly blue, with a central vertical black line representing the midline. There are some lighter blue and yellowish-green areas, particularly along the bottom edge, which may indicate areas of interest or pathology. The text "ABA:2607" is in the top left, and "A posterior" is in the bottom left.