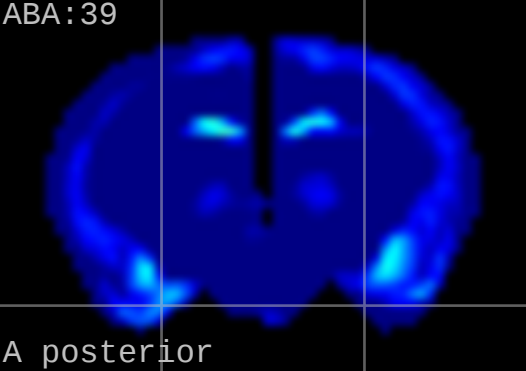


ABA: 39

A posterior

An axial brain scan image showing a cross-section of the brain. The image is predominantly blue, with some lighter blue and cyan areas indicating higher intensity or activity. The brain's structure, including the cerebral cortex and internal organs, is visible. The image is divided into four quadrants by a vertical and a horizontal white line. The text 'ABA: 39' is located in the top-left corner, and 'A posterior' is located in the bottom-left corner.