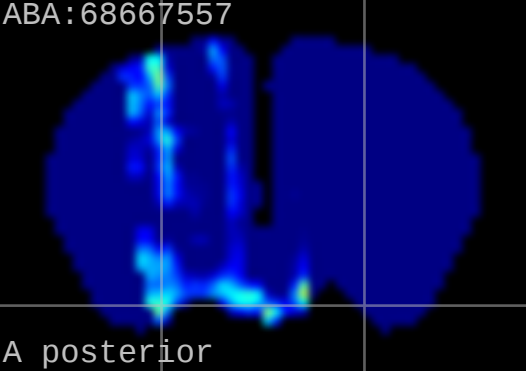


ABA: 68667557

A posterior

A brain scan image, likely an fMRI or PET scan, showing activation in the left hemisphere. The image is a grayscale slice of a brain, with a vertical line indicating the midline. The left side of the image (patient's right) shows several areas of activation, indicated by yellow and red colors. The right side of the image (patient's left) is mostly dark, indicating no significant activation. The text 'ABA: 68667557' is at the top, and 'A posterior' is at the bottom.