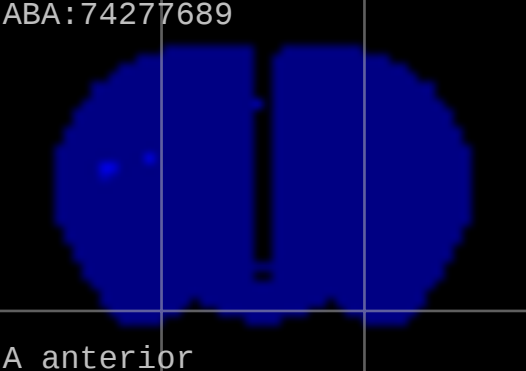


ABA: 69262116

A anterior

An axial brain scan image showing a focal hyperintense lesion in the left hemisphere. The image is overlaid with a white grid. The text 'ABA: 69262116' is at the top left, and 'A anterior' is at the bottom left. The lesion is a bright white spot in the left hemisphere, approximately in the middle of the image.