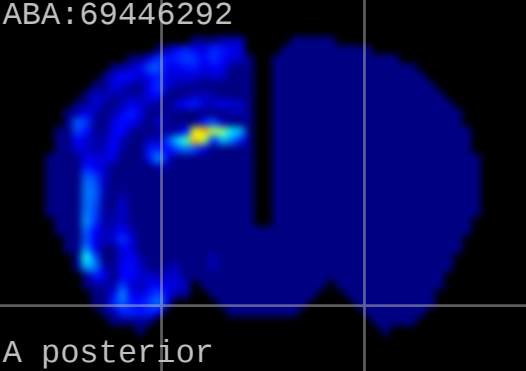


ABA: 69446292

A posterior

An axial PET scan of the brain. The image shows a cross-section of the brain with a color scale from blue (low uptake) to yellow (high uptake). A focal area of increased uptake is visible in the posterior region, specifically in the posterior horns of the lateral ventricles. The rest of the brain shows relatively low uptake. A vertical white line is drawn through the center of the brain, and a horizontal white line is drawn below the brain, intersecting at the focal area.