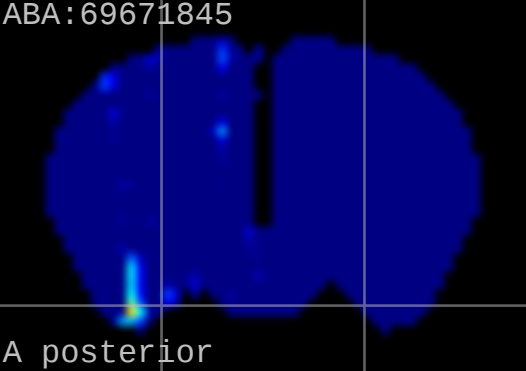


ABA: 69671845

A posterior

An axial brain scan image showing a focal area of high intensity (yellow/red) in the posterior region, likely indicating a lesion or abnormality. The rest of the brain is shown in blue. The image is overlaid with a white grid. The text "ABA: 69671845" is at the top left, and "A posterior" is at the bottom left.