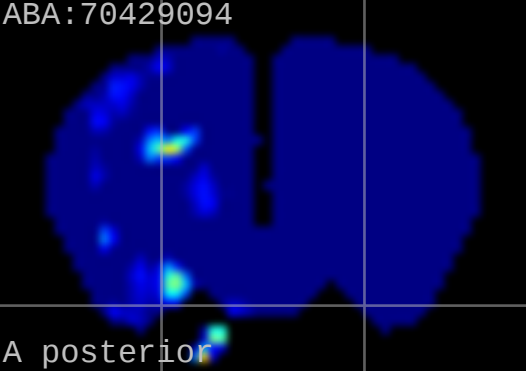


ABA:70429094

A posterior

A brain scan image, likely an fMRI or PET scan, showing activation in the left hemisphere. The image is a grayscale representation of a brain slice, with a vertical line indicating the midline. The left side of the image (viewer's left) shows several areas of activation, indicated by yellow and red colors. The most prominent activation is a large, bright yellow/red area in the posterior region, which is labeled "A posterior". There are also smaller, less intense activation spots in the anterior and middle regions of the left hemisphere. The right hemisphere (viewer's right) shows minimal to no activation. The overall image is framed by a white border.