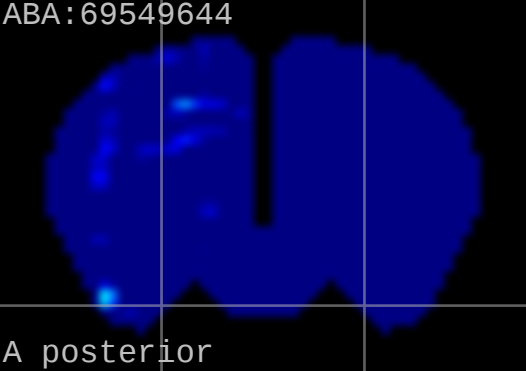


ABA: 71232740

A posterior

The image displays a cross-sectional view of a human brain, likely from an axial MRI or PET scan. The brain is rendered in shades of blue against a black background. A vertical white line is positioned on the left side of the image, and a horizontal white line is positioned at the bottom. A small, bright blue spot is visible in the lower-left quadrant of the brain, indicating a focal area of activation or abnormality. The text 'ABA: 71232740' is located at the top left, and 'A posterior' is at the bottom left.