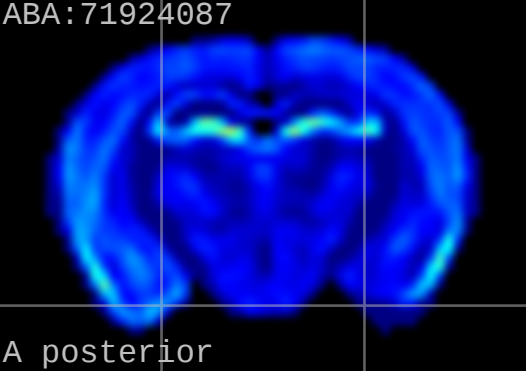


ABA:71924087

A posterior

An axial PET scan of the brain. The image shows a cross-section of the brain with a color scale from blue (low uptake) to yellow/red (high uptake). A prominent focal area of increased uptake is visible in the posterior region, specifically in the occipital cortex. The rest of the brain shows relatively low, uniform uptake. A white grid is overlaid on the image, with a vertical line passing through the center and a horizontal line passing through the focal area.