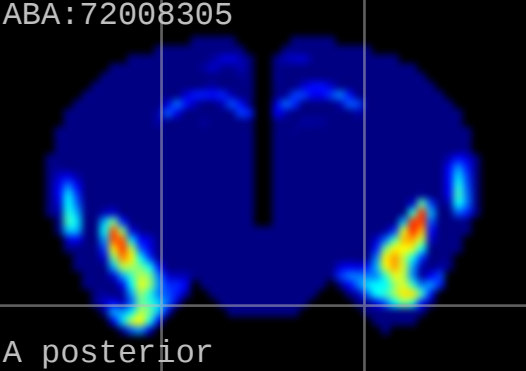


ABA:72008305

A posterior



This is an axial PET scan of the brain. The image shows a cross-section of the brain with a color scale from blue (low activity) to red (high activity). Two prominent areas of high activity are visible in the posterior regions of both hemispheres, likely corresponding to the occipital and parietal lobes. The rest of the brain shows relatively low activity, indicated by blue and cyan colors. A vertical white line is drawn through the center of the brain, and a horizontal white line is drawn across the middle of the image.