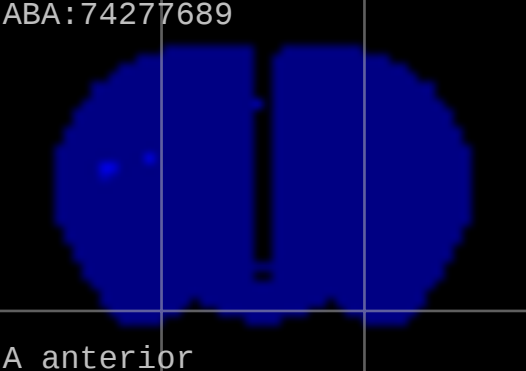


ABA:74277689

A anterior

An axial MRI scan of a human brain. The image is in grayscale. A red overlay is visible on the left side of the image, indicating a specific region of interest. The brain's internal structures, including the ventricles and cortical gyri, are visible. A vertical white line is drawn through the center of the brain, and a horizontal white line is drawn across the middle. The text 'ABA:74277689' is at the top left, and 'A anterior' is at the bottom left.