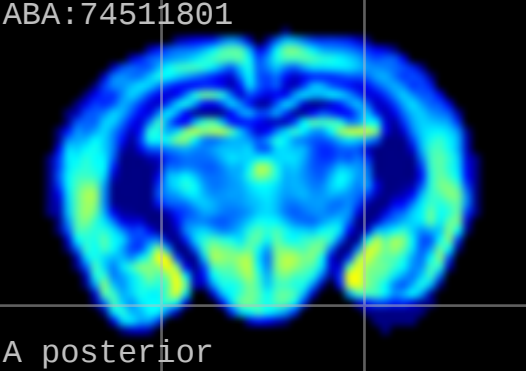


ABA:74511801

A posterior

An axial PET scan of the brain. The image shows a cross-section of the brain with a color scale from blue (low activity) to yellow (high activity). The brain's anatomy is visible, including the cerebral cortex, white matter, and central structures. There are several areas of increased metabolic activity, particularly in the posterior and lateral regions. A vertical white line is drawn through the center of the brain, and a horizontal white line is drawn across the bottom of the image.