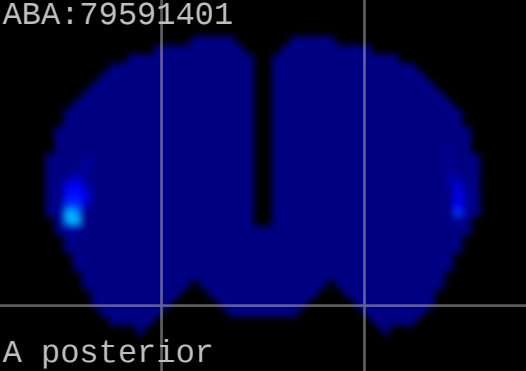


ABA:77867710

A posterior

The image displays a posterior view of a brain scan. A prominent, bright blue focal lesion is visible in the posterior region, centered between the two hemispheres. The rest of the brain tissue appears dark, indicating low signal intensity. A white crosshair is overlaid on the image, with the vertical line passing through the center of the lesion and the horizontal line passing through the lower part of the brain.